


Brady's and Blocks The Brady Bunch!!!

Todd Haber MD FACEP

LRH ED

Todd.Haber@myLRH.org

A Very Brady Day



Props and Kudos

- Dr. Amal Mattu
Mentorship and guidance
- www.ecgweekly.com
The little website that could...
- www.lifeinthefastlane.com
Gazillions of images

Disclosures

I get NOTHIN'

From EVERYBODY

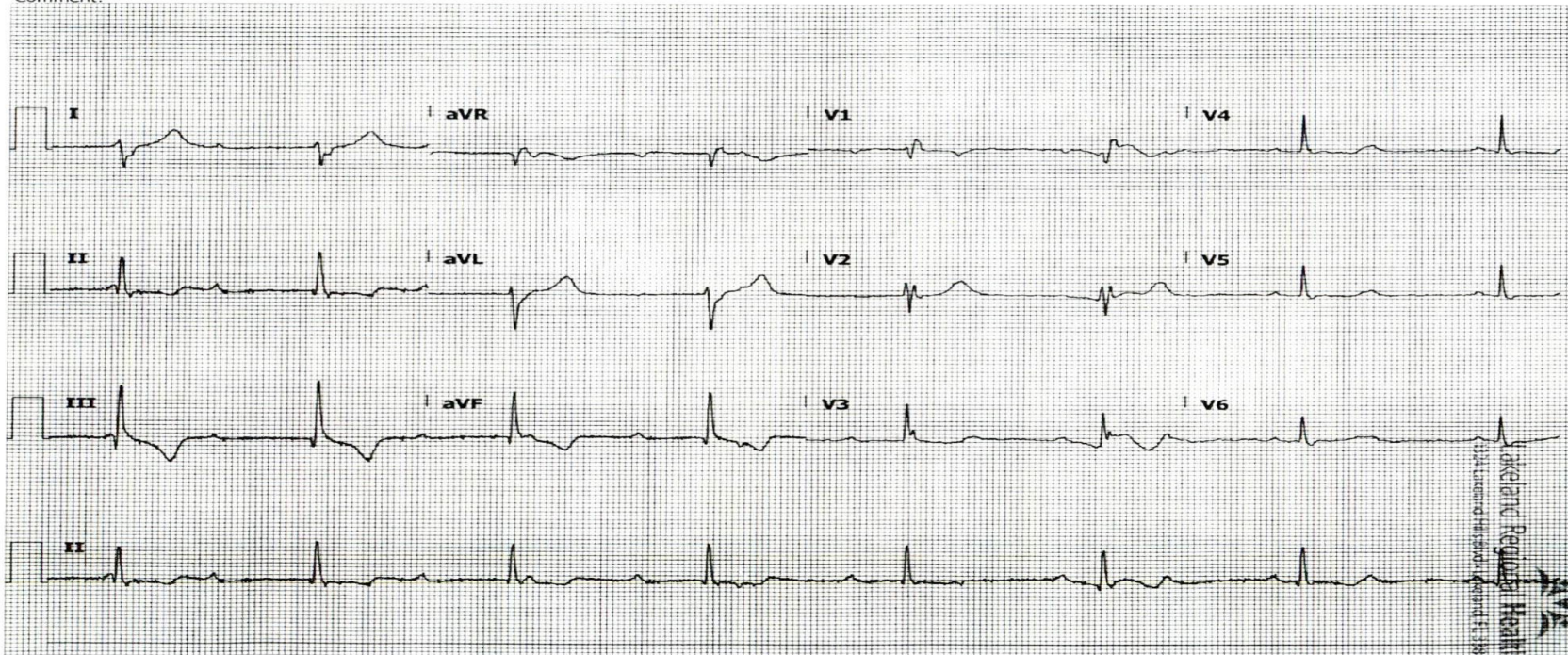
Tough Cases
What's your call???

57 y.o "weak and lightheaded"

ID: [REDACTED]
DOB: 1/15/1960, 57 yr
Female
Location: [REDACTED]
Operator: 130
Referred by: [REDACTED]
Requested by: [REDACTED]
Comment:

12/10/2017 13:42:20
Vent rate: 45 BPM
PR int: 0 ms
QRS dur: 139 ms
QT/QTc: 483/ 440 ms
P-R-T axes: 999 109 -30
Avg RR: 1306 ms

UNCERTAIN IRREGULAR RHYTHM
MARKED RIGHT AXIS DEVIATION [QRS AXIS > 100]
RIGHT BUNDLE BRANCH BLOCK [120+ ms QRS DURATION, UPRIGHT V1, 40+ ms S IN I/aVL/V4/V5/V6]
ABNORMAL ECG
Unconfirmed Report 12/10/2017 13:42:20



E-Scribe DICOM Module 1.30.6

LPMC

25 mm/s 10 mm/mV 0.05-300 Hz

59 yo w/ "palpitations"

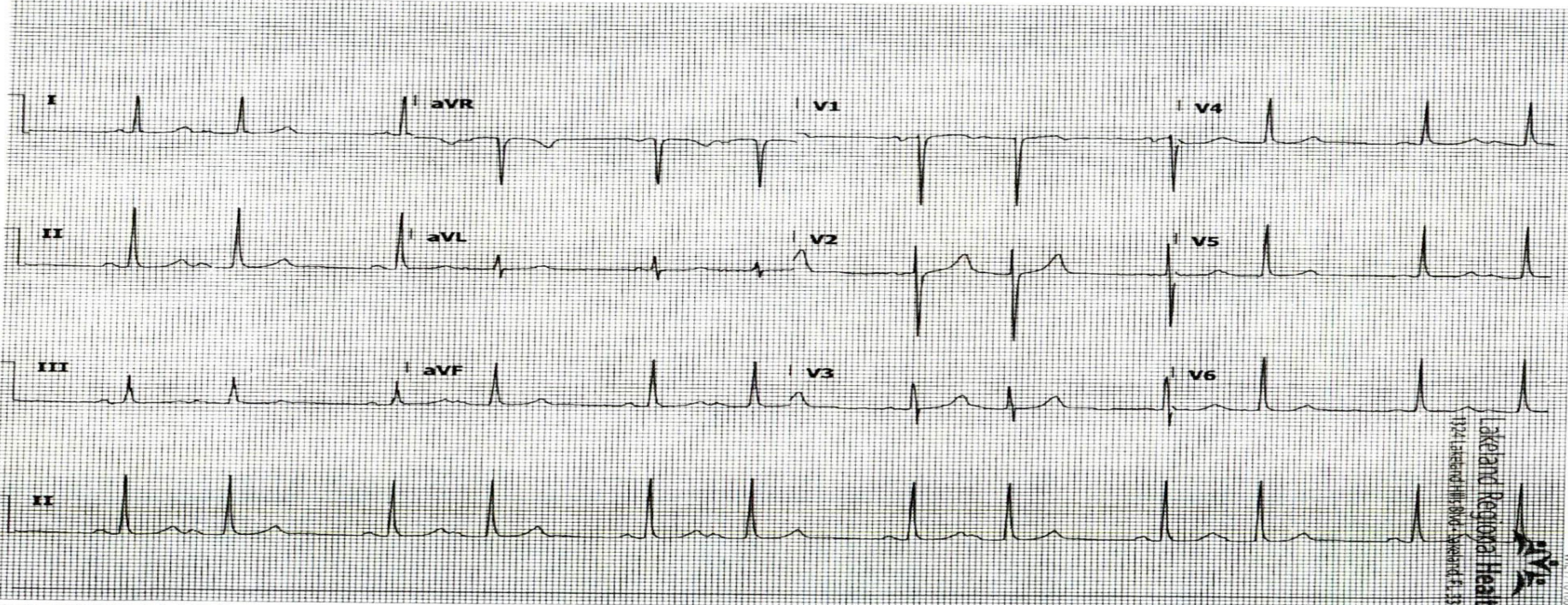
CPPT05041 10:17

DOB: 3/22/1958, 59 yr
Gender: male
Location: E01 - Triage-TLOB-02
Operator: 10836
Referred by:
Requested by: EMERGENCY PHYSICIAN
Comment:

11/28/2017 14:00:03
Vent rate: 72 BPM
PR int: 0 ms
QRS dur: 85 ms
QT/QTc: 409/ 433 ms
P-R-T axes: 999 55 44
Avg RR: 831 ms

SINUS RHYTHM WITH 2ND DEGREE AV BLOCK, MOBITZ TYPE II

ABNORMAL ECG



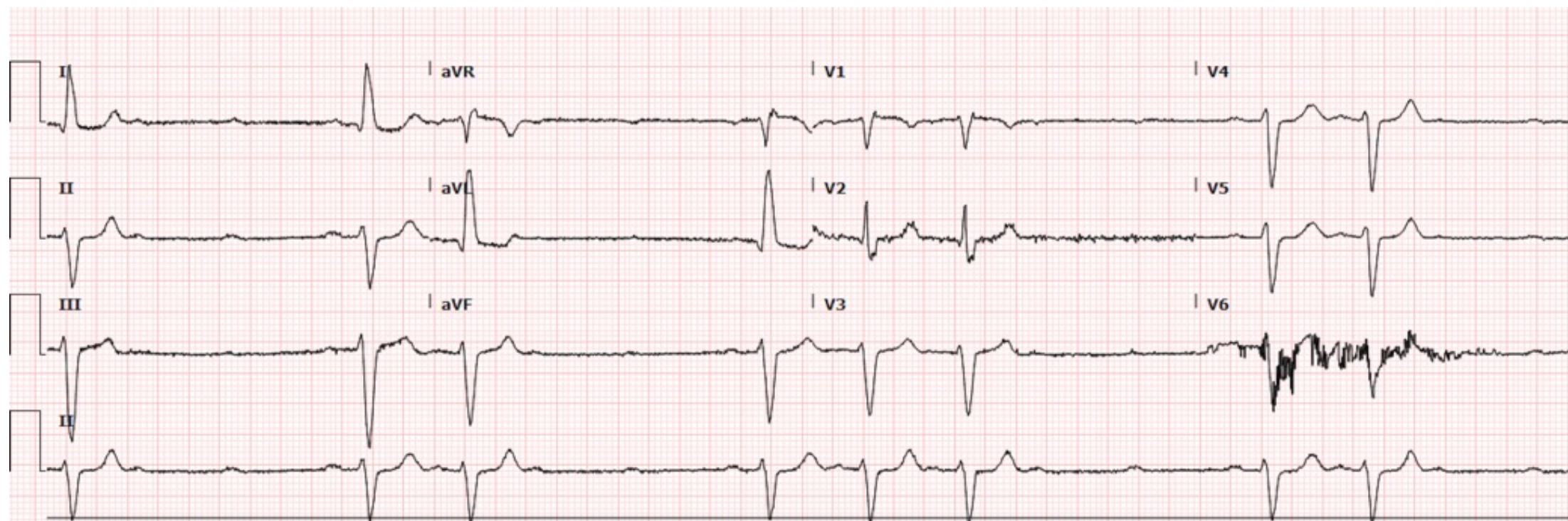
-Scribe DICOM Module 1.30.6

LRMC

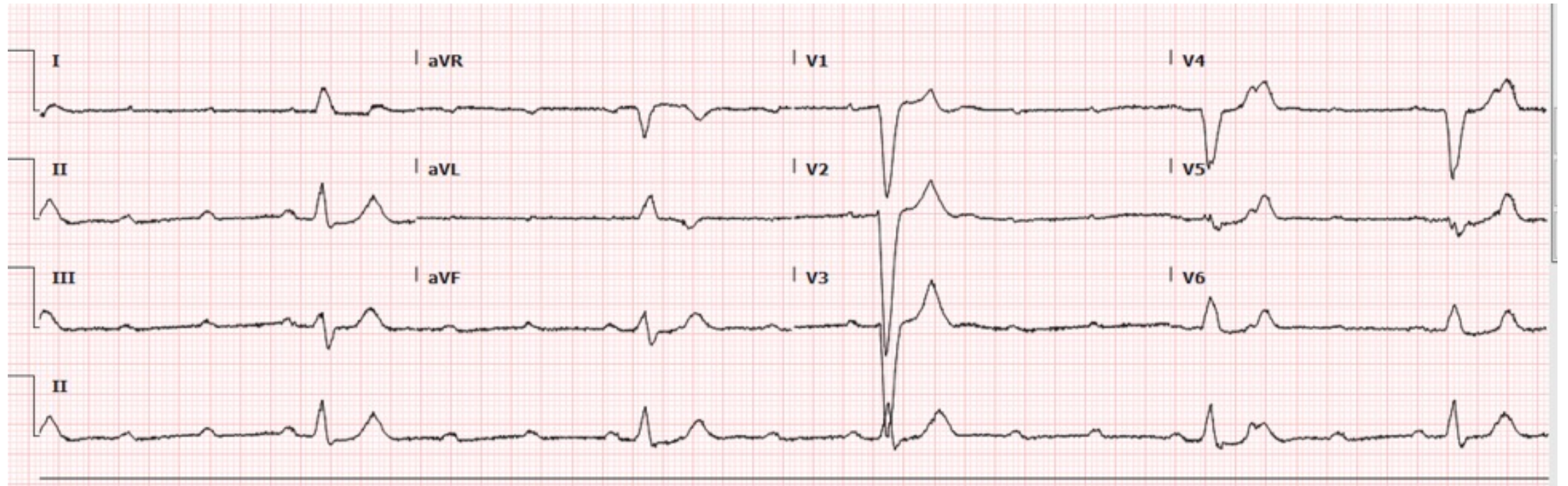
25 mm/s 10 mm/mV 0.05-300 Hz

Lakeview Regional Health
1221 Lakeside Blvd - Sheboygan, WI 53081
WV 171180005

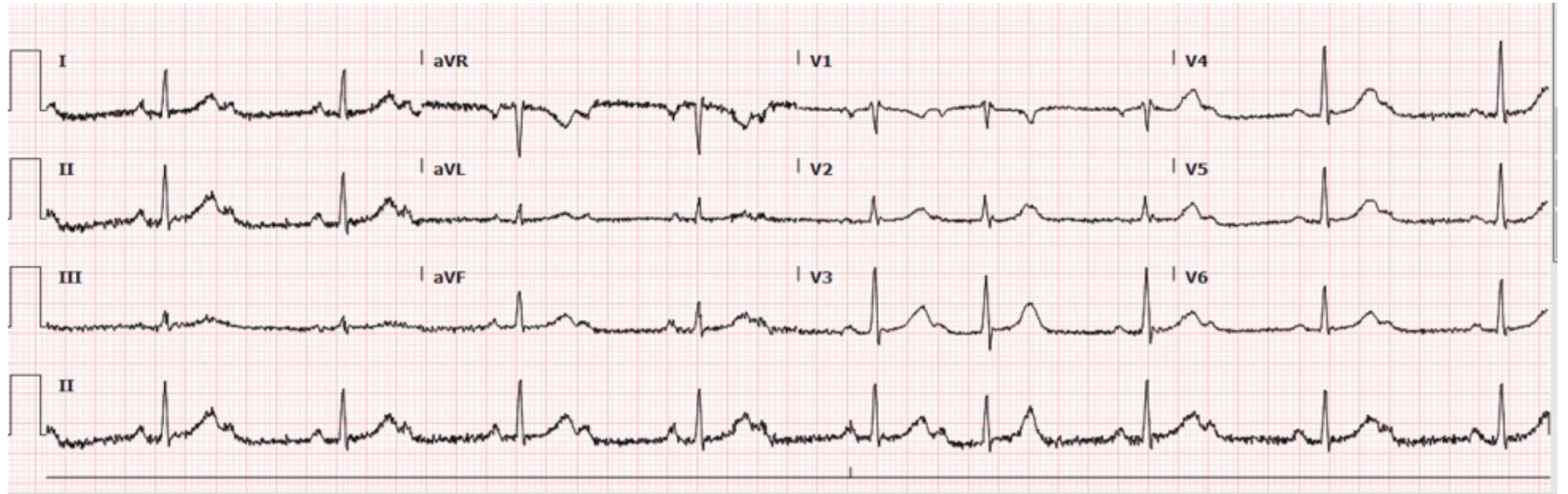
70 y.o. weakness



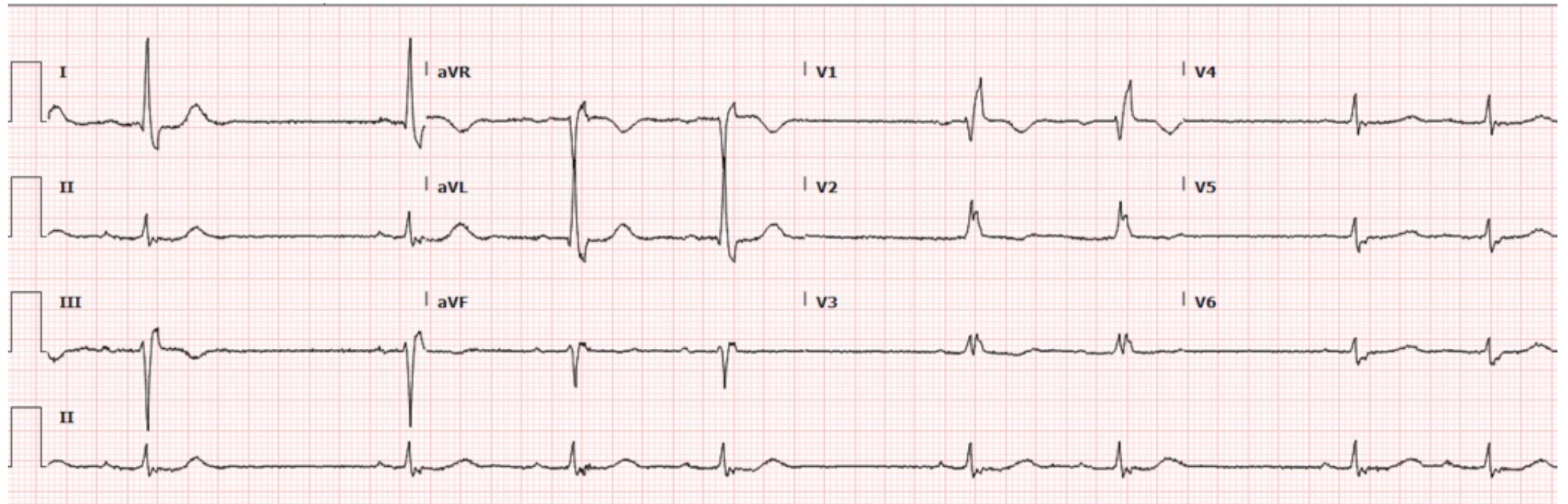
70 yo near syncope



60 yo. On Beta Blockers Light-headed



94 yo Dizzy Irreg Heart Beat



ECG INTERPRETATION

same system-every time

- Rate
- Rhythm
- Axis
- Intervals
- Ischemia
- Enlargement/Hypertrophy

Rhythm

What are the ventricles doing? QRS

- How many morphologies?

- Regular/Irregular?

Irregularly irreg. or regularly irreg.?

- Wide/Narrow?

What are the atria doing? P wave

- Are there P waves?

How many morphologies?

- Where do P's Hide

V1, in QRS, in T wave

Look in all leads

- Upright II? Negative Avr?

- Regular? Check P-P interval

Are P's and QRS's "Married"?

- Is every P followed by QRS?
If no-too many P's (blocks)

- Is every Q preceded by P?
If no - too many QRS (extra beats)

Rate Pacemaker Function

- SA node (60-100 bpm)
- AV node (40-50 bpm)
- His-Purkinje (25-35 bpm)

Bradycardia

Ventricular/QRS < 60 BPM

- QRS

How many morphologies?

Regular/Irregular?

Wide/Narrow?

- P waves present?

Look in all leads

Check V1

Check T waves (pokey)

Bradycardia

What's the Rhythm???

P waves present

- Is every P followed by QRS?
 - If NO non conducted P's/blocks
- Is every QRS preceded by P?
 - If NO "extra beats"

P waves absent

- QRS

Regular/irregular?

Wide/narrow?

Bradycardia

P waves present

- No non conducted P's
Sinus Bradycardia/Sinus Pauses
- Non conducted P's
 - Mobitz I
 - Mobitz II
 - 3rd degree HBSinus rhythm w/ blocked Apc's

P waves absent

- Junctional Escape
- Ventricular Escape
- Atrial fibrillation w/slow VR

Non conducted P's

- Check P-P intervals
- Check P-R intervals

Non Conducted P's

P-P's regular/map

Check P-R interval

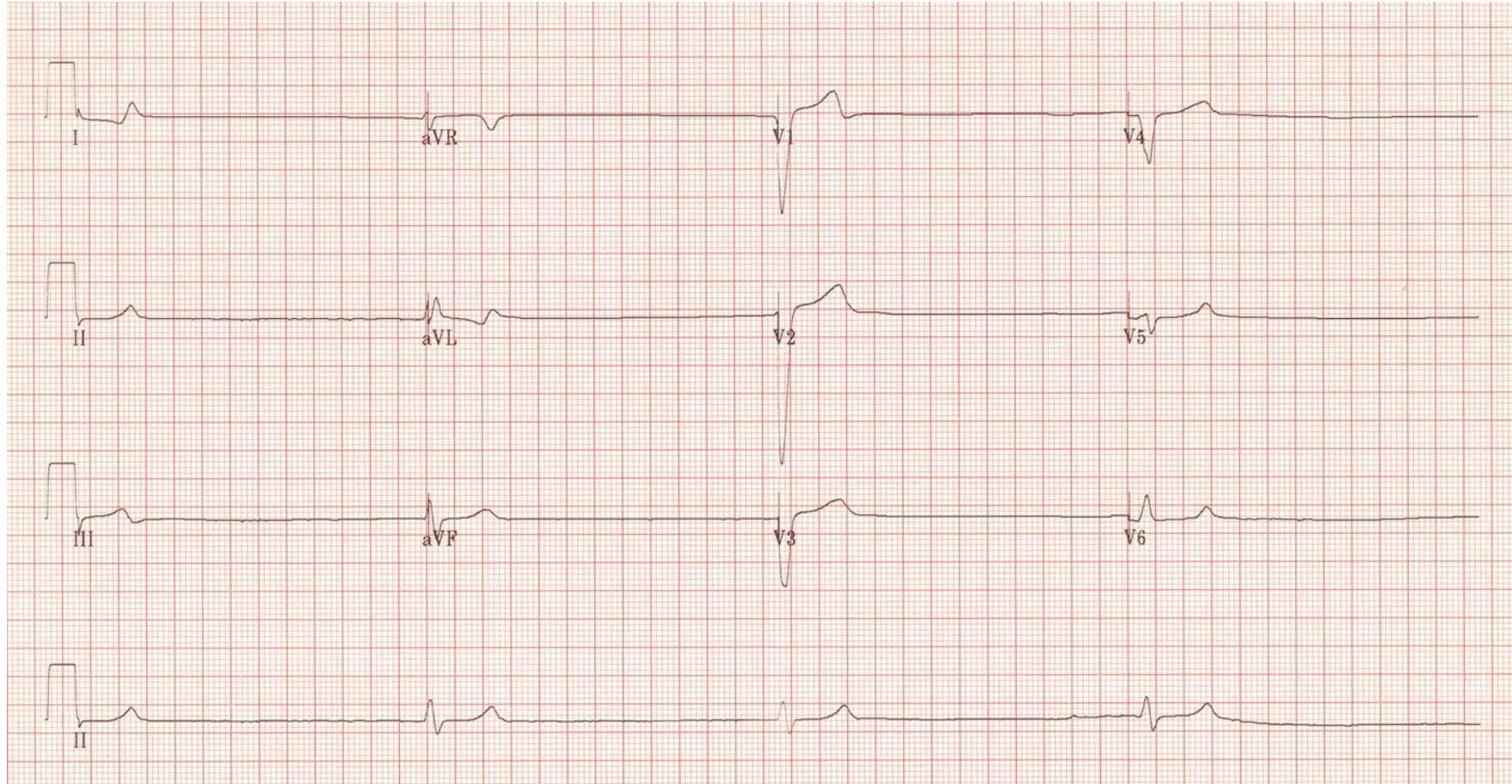
- Mobitz I
- PR prolong then drop
- Mobitz II
- PR constant then drop
- 3rd degree Block
 - PR varies/random

P-P's irregular

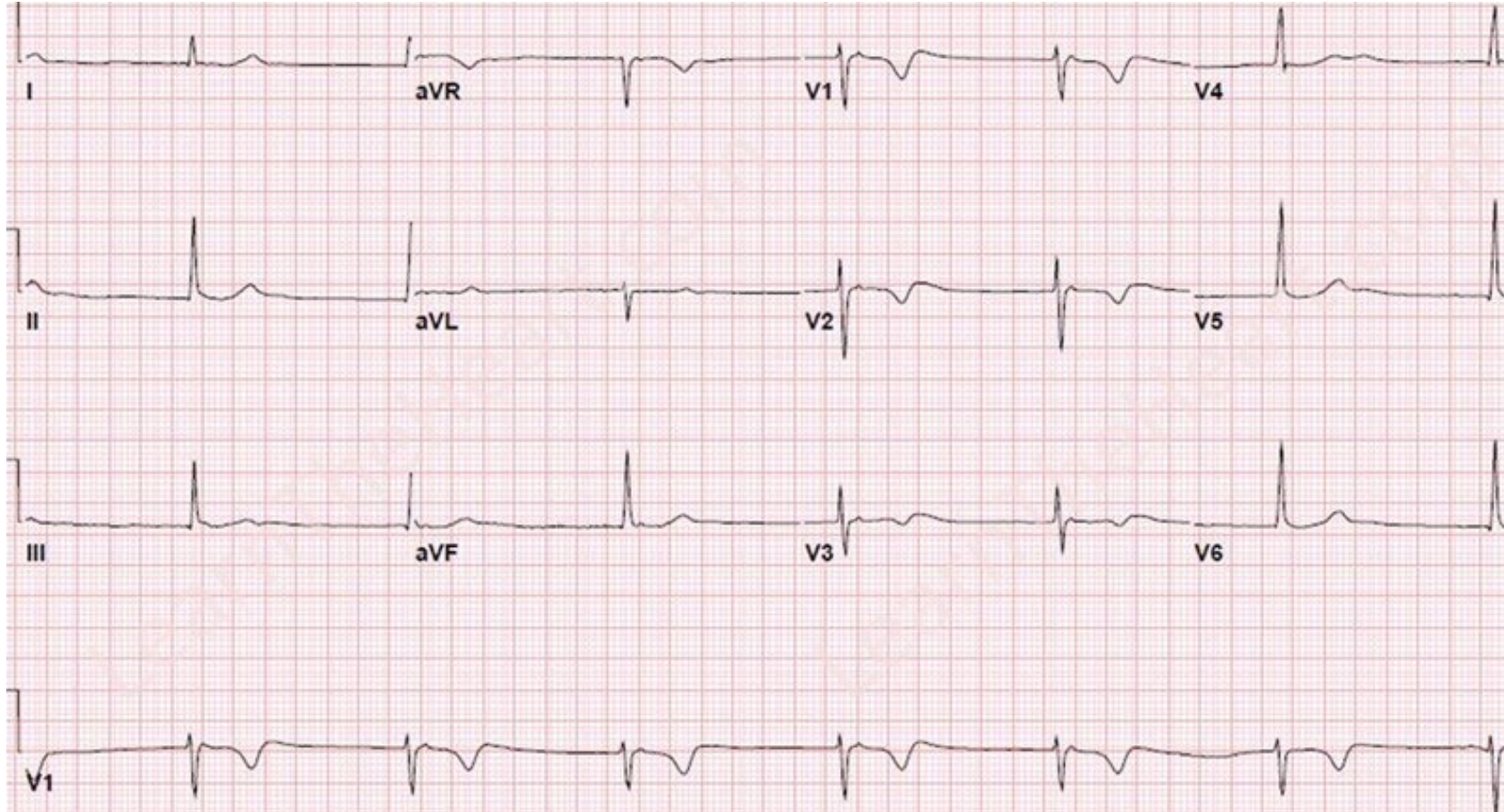
Don't map

- Sinus w/Blocked APC's

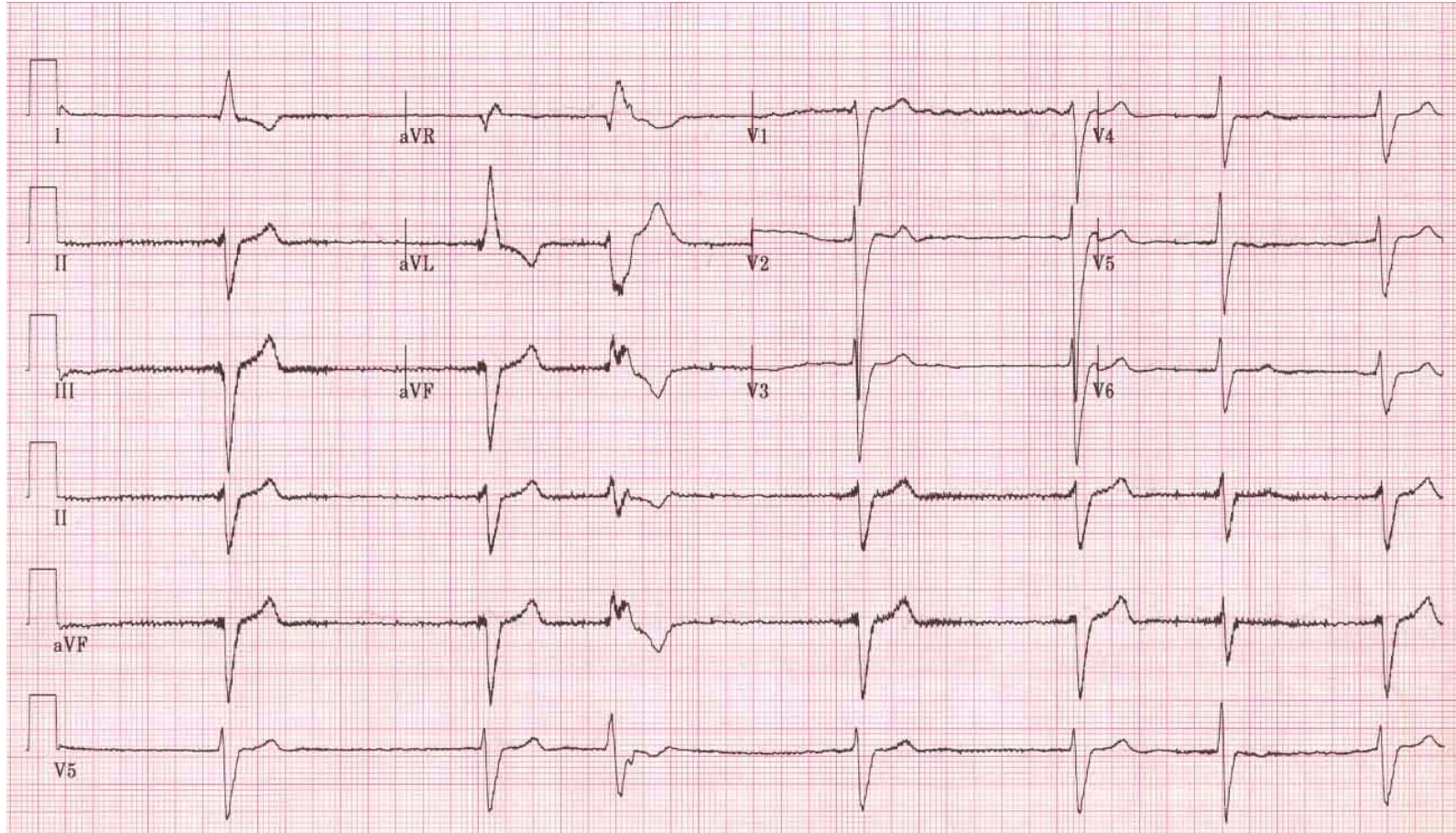
P waves absent Ventricular Rhythm



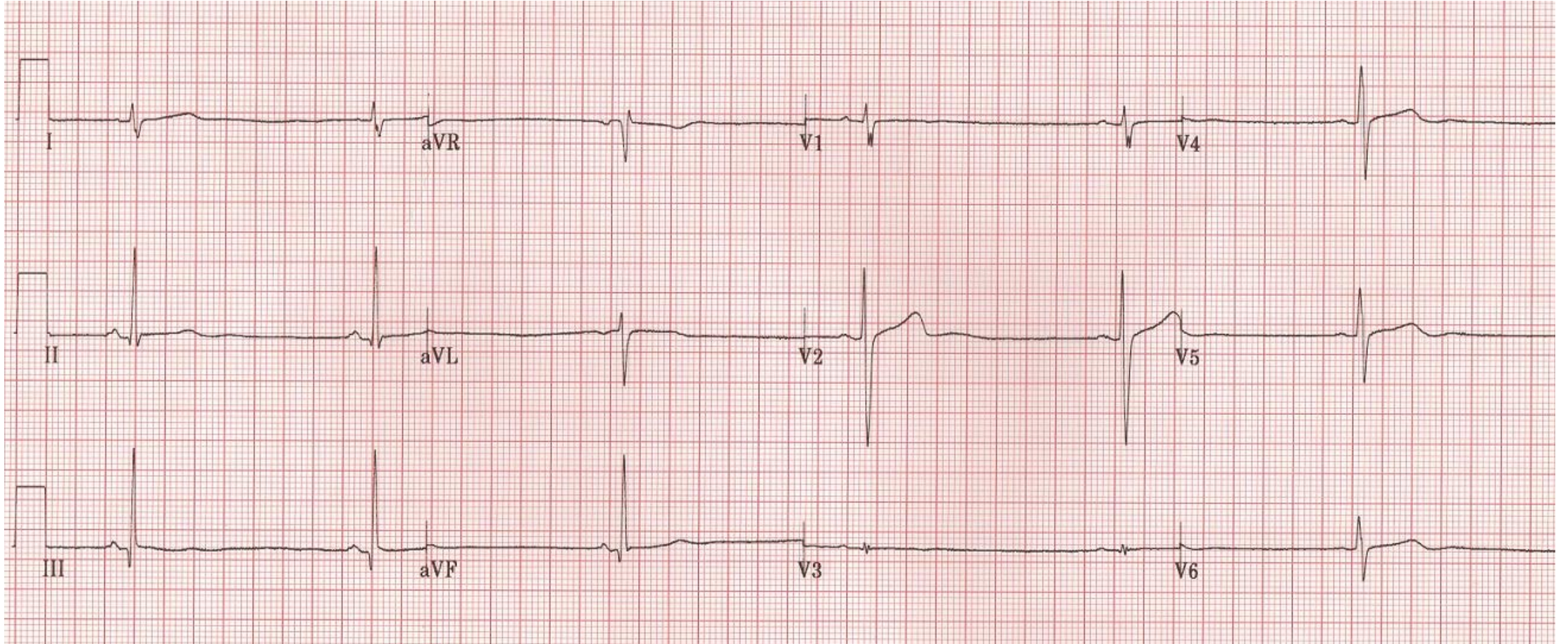
P waves absent Junctional Rhythm



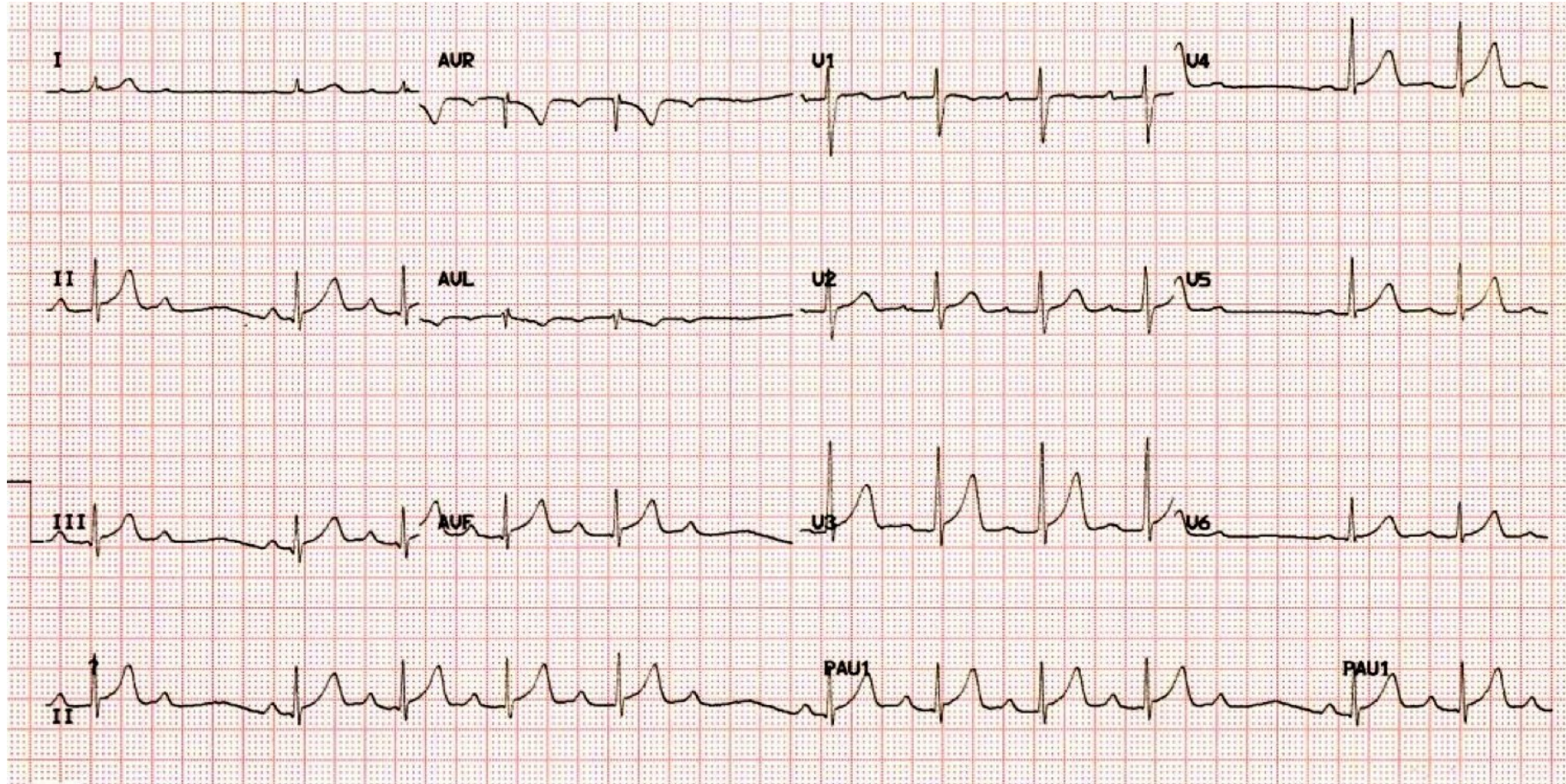
P waves absent
Afib w/slow VR



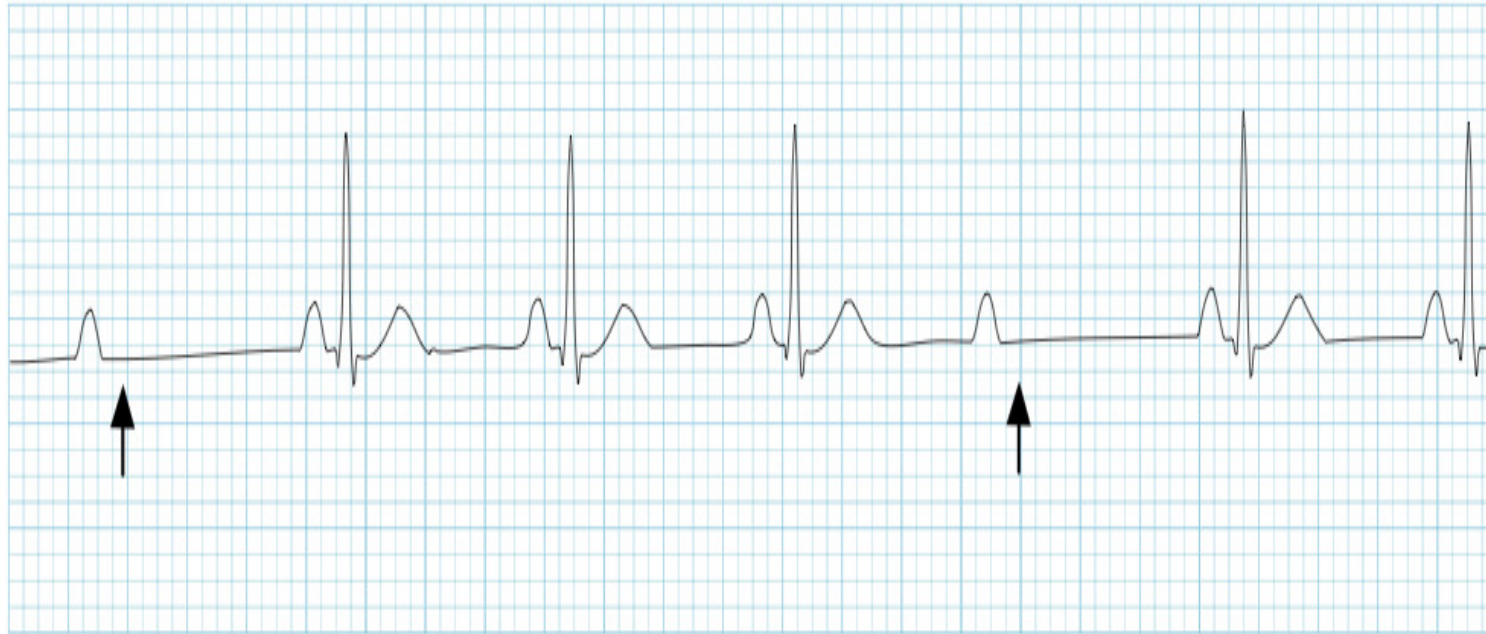P waves present
No Non Conducted P's
Sinus Bradycardia



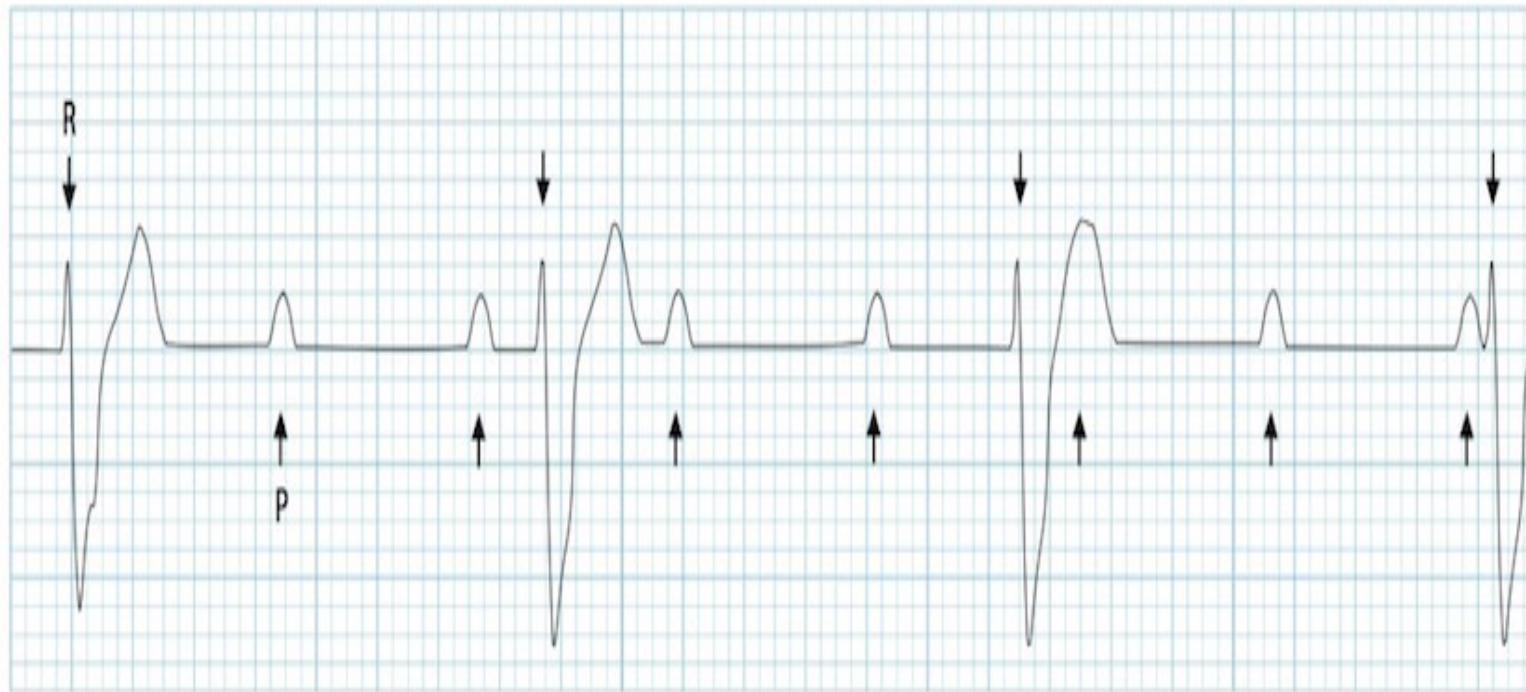
P waves present
Non Conducted P's
RSR w/Mobitz I



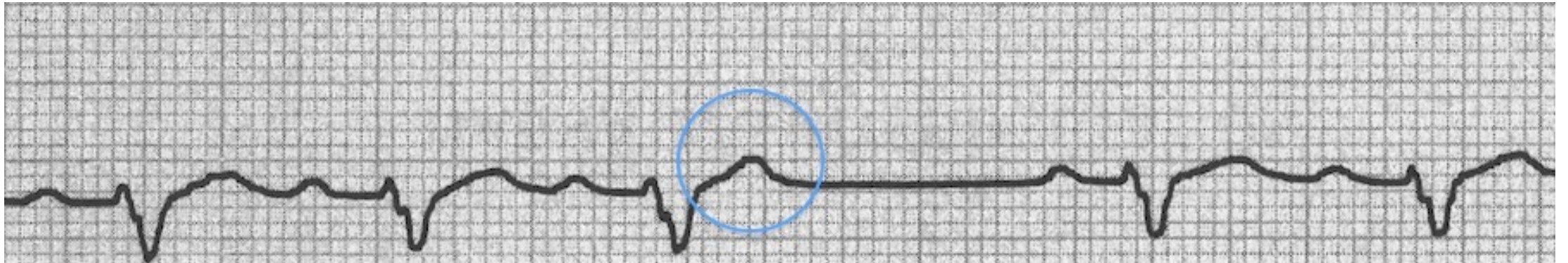
P wave Present
Non Conducted P's
RSR w/Mobitz II

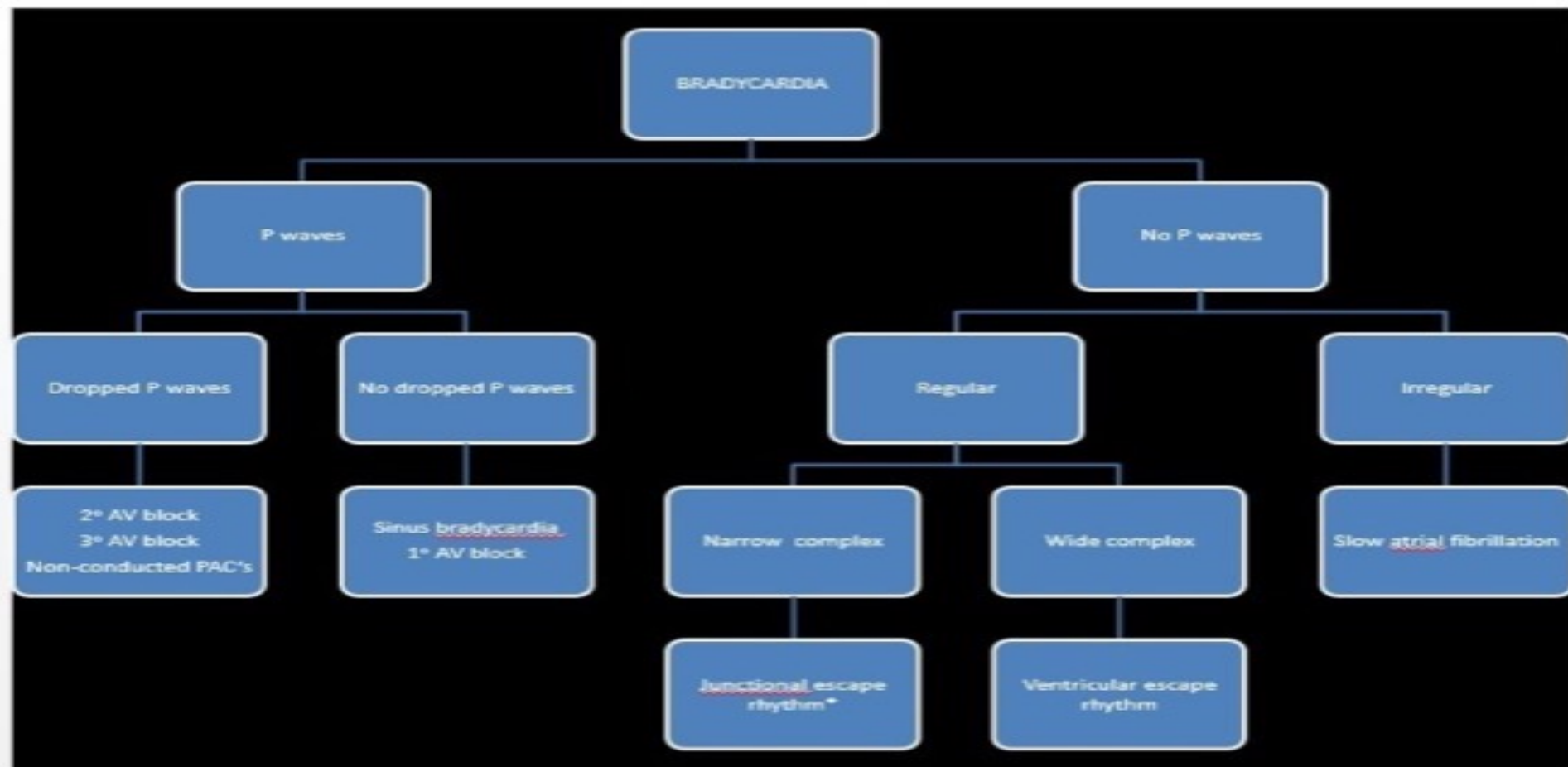


P waves present
Non Conducted P's
3rd degree HB



P waves present
Non Conducted P's
RSR w/blocked APC's





Hyperkalemia

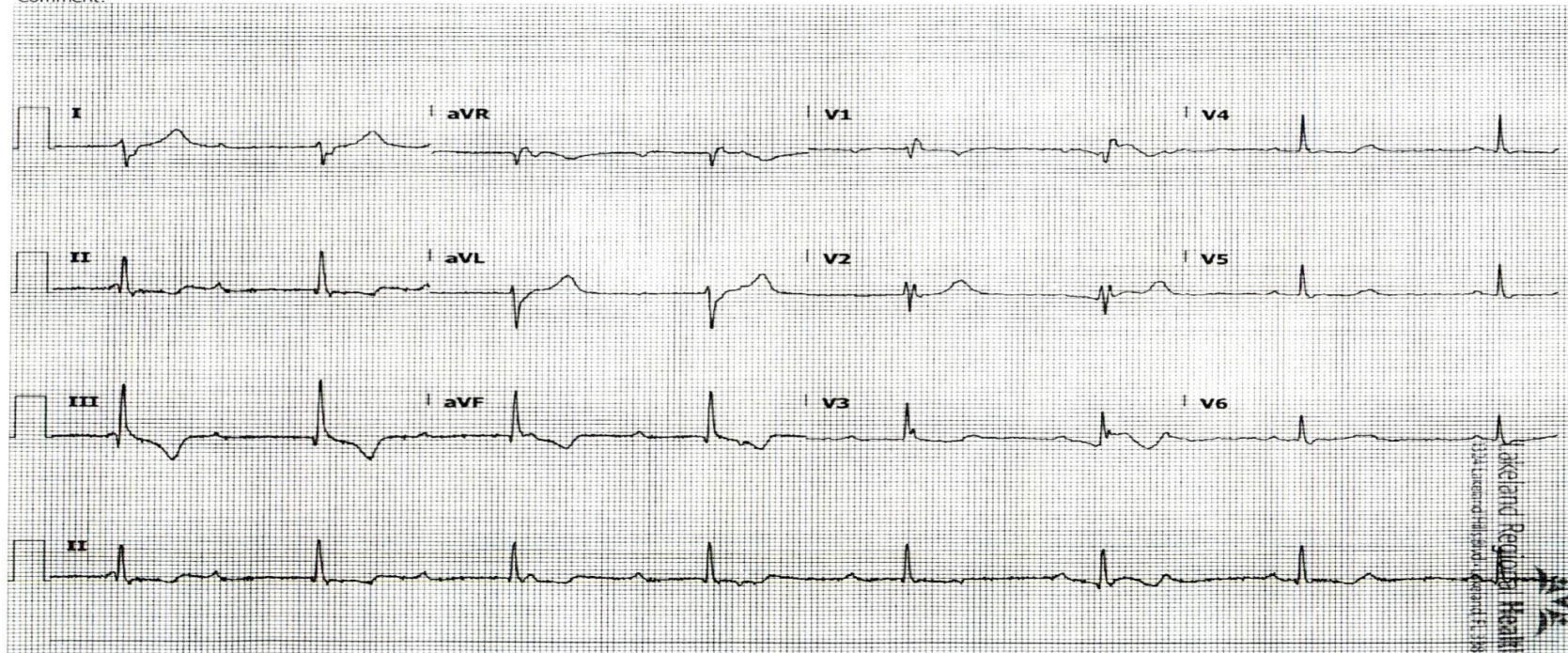
- Peaked T waves (pointy)
- Widened QRS (rare in STEMI)
 - Prolonged PR
 - Flat/Loss of P waves
 - AV Blocks
 - BBB's
- STE R sided leads 2/3/F V1 V2
 - RAD (rare in STEMI)

Case #1

ID: [REDACTED]
DOB: 1/15/1960, 57 yr
Female
Location: [REDACTED]
Operator: 130
Referred by: [REDACTED]
Requested by: [REDACTED]
Comment:

12/10/2017 13:42:20
Vent rate: 45 BPM
PR int: 0 ms
QRS dur: 139 ms
QT/QTc: 483/ 440 ms
P-R-T axes: 999 109 -30
Avg RR: 1306 ms

UNCERTAIN IRREGULAR RHYTHM
MARKED RIGHT AXIS DEVIATION [QRS AXIS > 100]
RIGHT BUNDLE BRANCH BLOCK [120+ ms QRS DURATION, UPRIGHT V1, 40+ ms S IN I/aVL/V4/V5/V6]
ABNORMAL ECG
Unconfirmed Report 12/10/2017 13:42:20



E-Scribe DICOM Module 1.30.6

LRMC

25 mm/s 10 mm/mV 0.05-300 Hz

Wakefield Regional Health
333 Wakefield Street, Wakefield, MA 01880
www.wakefieldregional.com

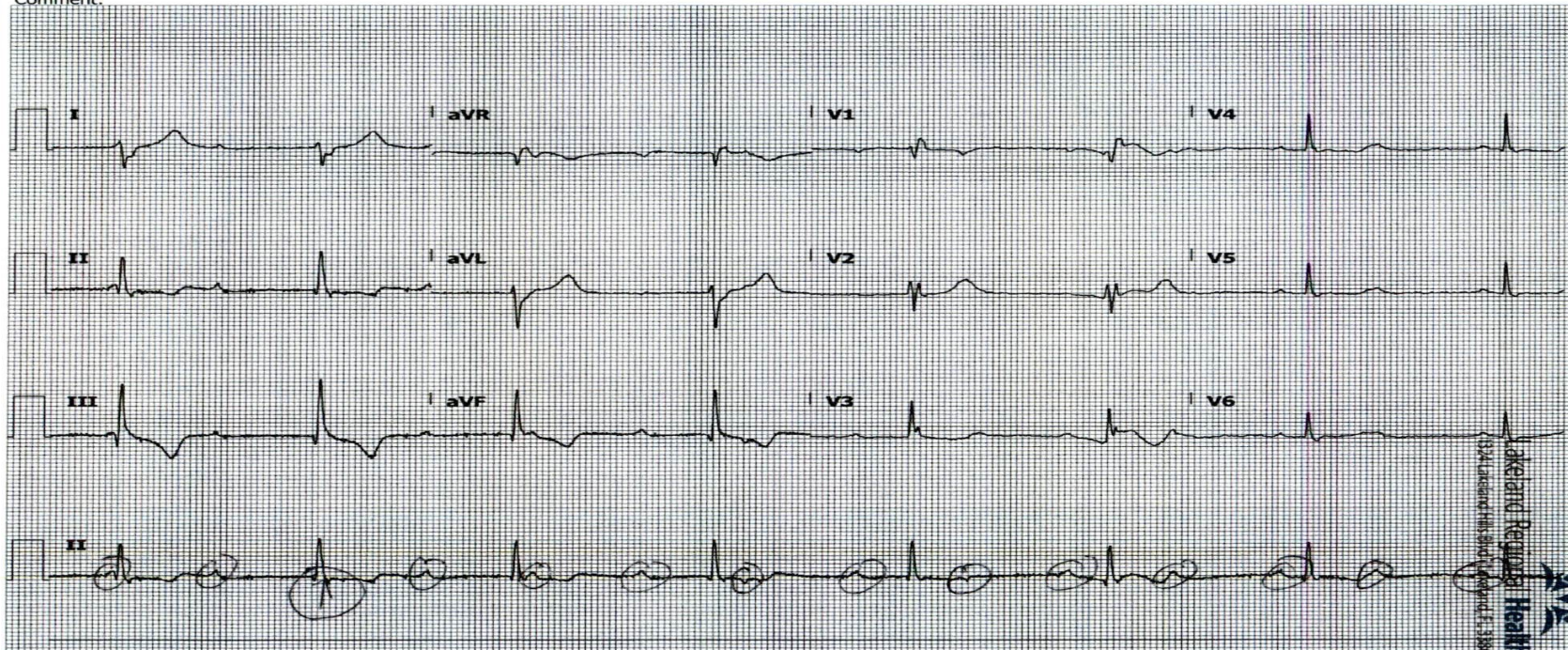
Check out the hidden P's!!!

12/10/2017 13:42:20

ID: [REDACTED]
DOB: 1/15/1960, 57 yr
Female
Location: [REDACTED]
Operator: 130
Referred by: [REDACTED]
Requested by: [REDACTED]
Comment:

12/10/2017 13:42:20
Vent rate: 45 BPM
PR int: 0 ms
QRS dur: 139 ms
QT/QTc: 483/440 ms
P-R-T axes: 999 109 -30
Avg RR: 1306 ms

UNCERTAIN IRREGULAR RHYTHM
MARKED RIGHT AXIS DEVIATION [QRS AXIS > 100]
RIGHT BUNDLE BRANCH BLOCK [120+ ms QRS DURATION, UPRIGHT V1, 40+ ms S IN I/aVL/V4/V5/V6]
ABNORMAL ECG
Unconfirmed Report 12/10/2017 13:42:20



BLUE BACKGROUND, REFLECTIVE WATERMARK, SECURITY FEATURES LISTED ON BACK.

E-Scribe DICOM Module 1.30.6

LRMC

25 mm/s 10 mm/mV 0.05-300 Hz

LakeLand Regional Health
1324 Lakeland Hills Blvd., Lakeland, FL 33801
VHL171200001

Case #2

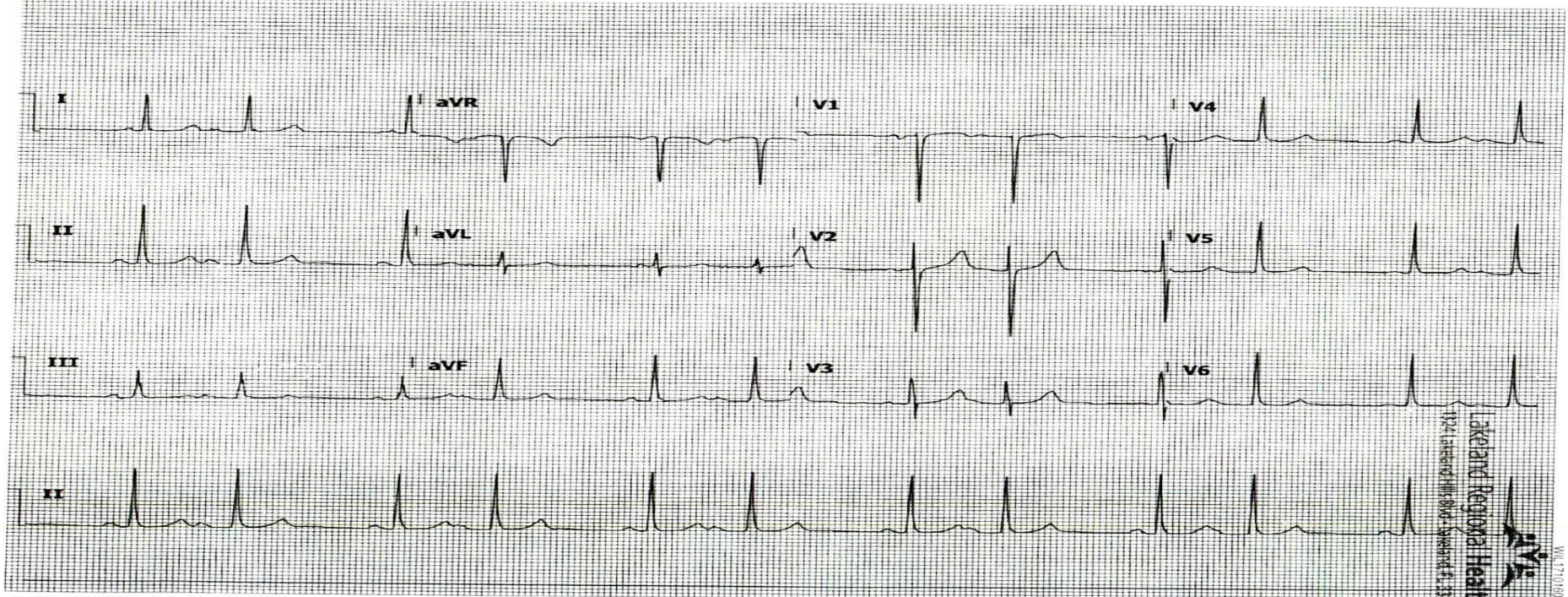
CPPT05041 10:17
11/28/2017 14:00:03

DOB: 3/22/1958, 59 yr
Sex: male
Location: E01 - Triage-TLOB-02
Operator: 10836
Referred by:
Requested by: EMERGENCY PHYSICIAN
Comment:

Vent rate: 72 BPM
PR int: 0 ms
QRS dur: 85 ms
QT/QTc: 409/ 433 ms
P-R-T axes: 999 55 44
Avg RR: 831 ms

SINUS RHYTHM WITH 2ND DEGREE AV BLOCK, MOBITZ TYPE II

ABNORMAL ECG
[REDACTED]



-Scribe DICOM Module 1.30.6

LRMC

25 mm/s 10 mm/mV 0.05-300 Hz

Lakeland Regional Health
1221 Lakeland Hill Blvd - Lakeland, FL 33801
WV 771-180005

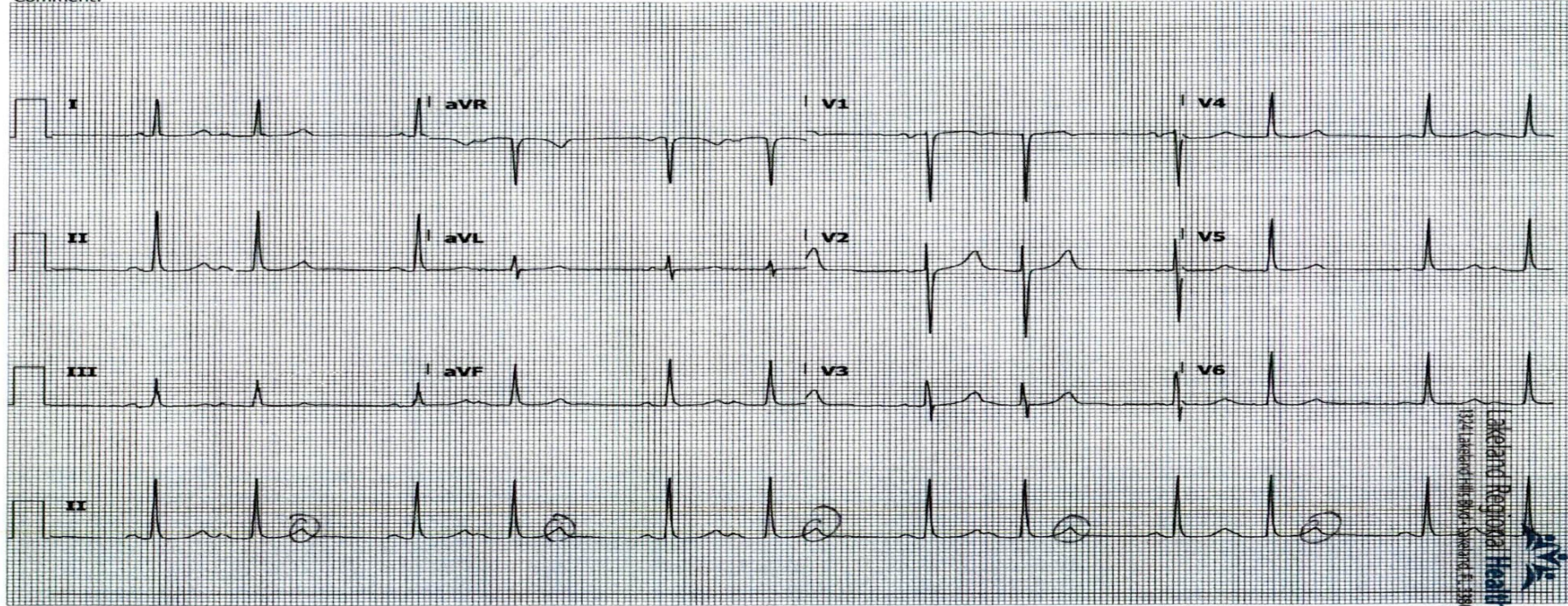
More Hidden P's!!!

PP25041-10-17

ID: [REDACTED]
DOB: 3/22/1958, 59 yr
Female
Location: E01 - Triage-TLOB-02
Operator: 10836
Referred by:
Requested by: EMERGENCY PHYSICIAN
Comment:

11/28/2017 14:00:03
Vent rate: 72 BPM
PR int: 0 ms
QRS dur: 85 ms
QT/QTc: 409/ 433 ms
P-R-T axes: 999 55 44
Avg RR: 831 ms

SINUS RHYTHM WITH 2ND DEGREE AV BLOCK, MOBITZ TYPE II
ABNORMAL ECG
Signed by: [REDACTED]



BLUE BACKGROUND REFLECTIVE WATERMARK SECURITY FEATURES LISTED ON BACK.

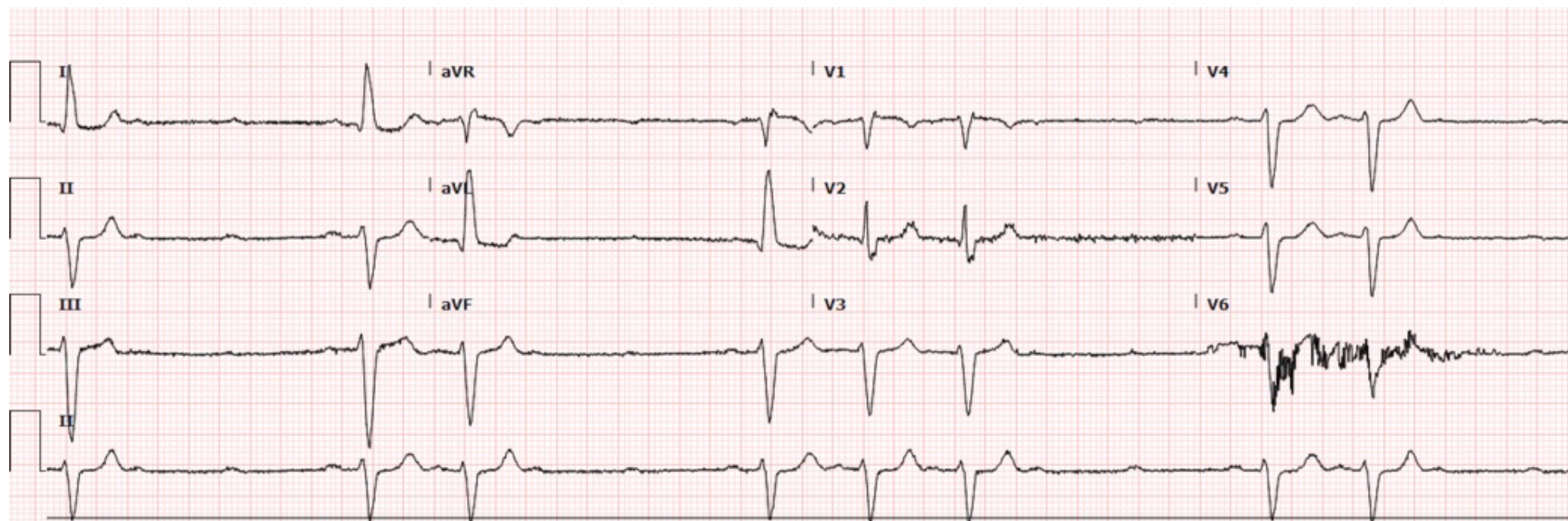
E-Scribe DICOM Module 1.30.6

LRMC

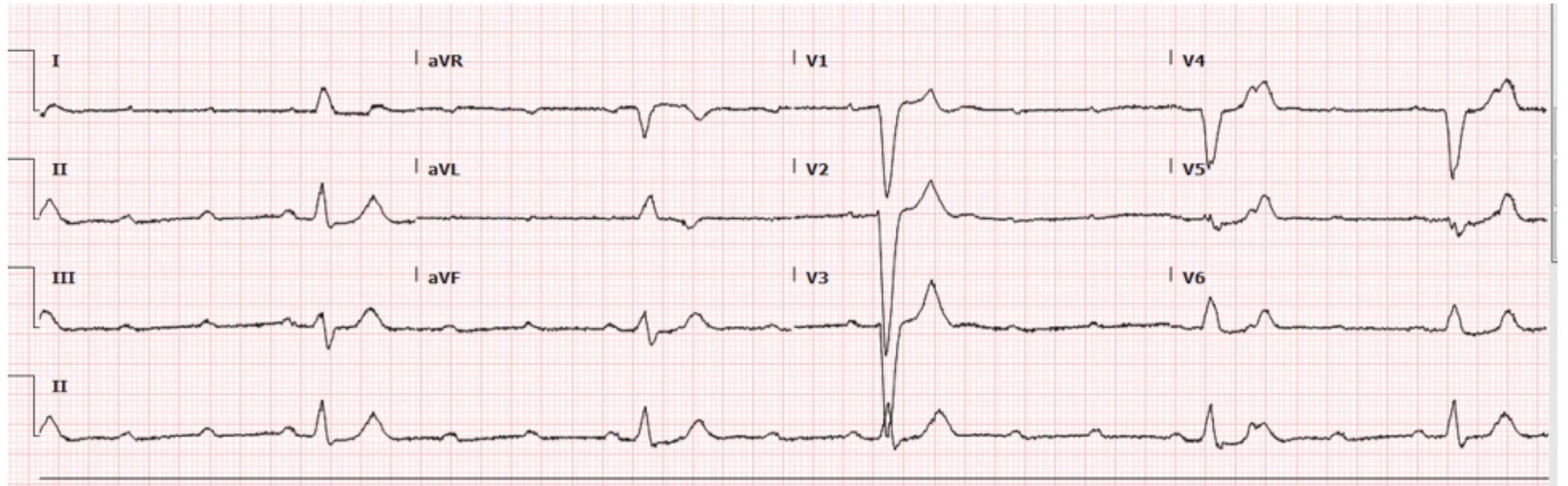
25 mm/s 10 mm/mV 605-300 Hz

Lakeand Regional Health
174 Argonne Hill Road, Newark, NJ 07105
WV 171018005

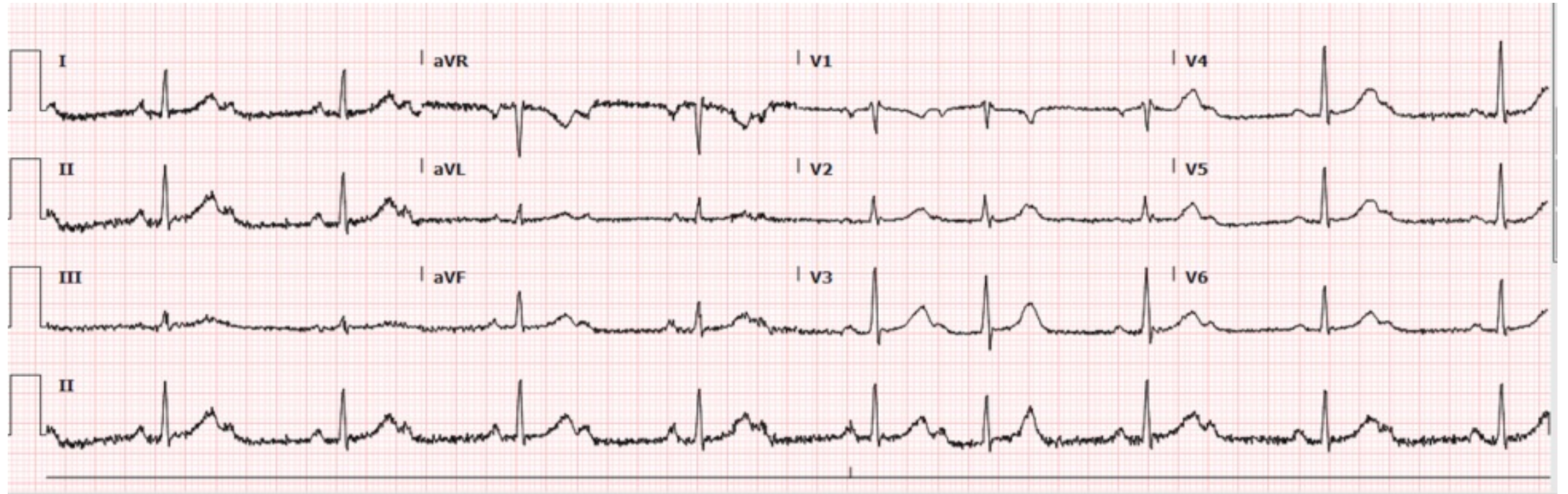
70 y.o. weakness



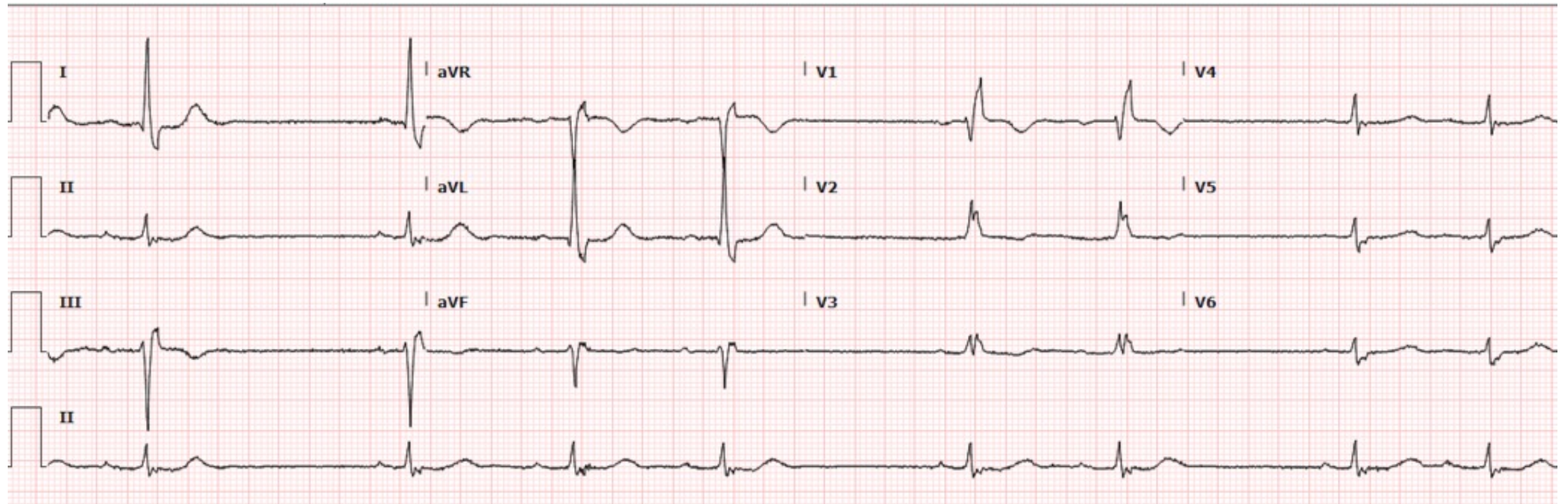
70 yo near syncope



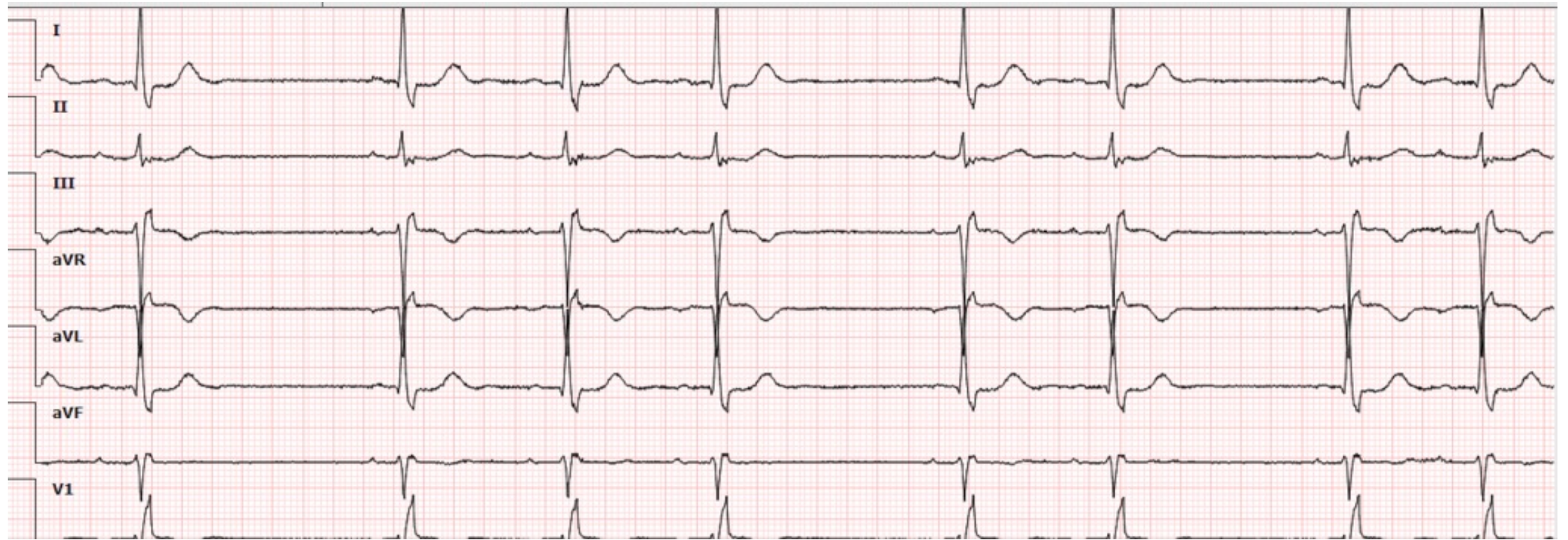
60 yo. On Beta Blockers Light-headed



94 yo Dizzy Irreg Heart Beat



12 X 1 Mode



Thanks for playing....



